

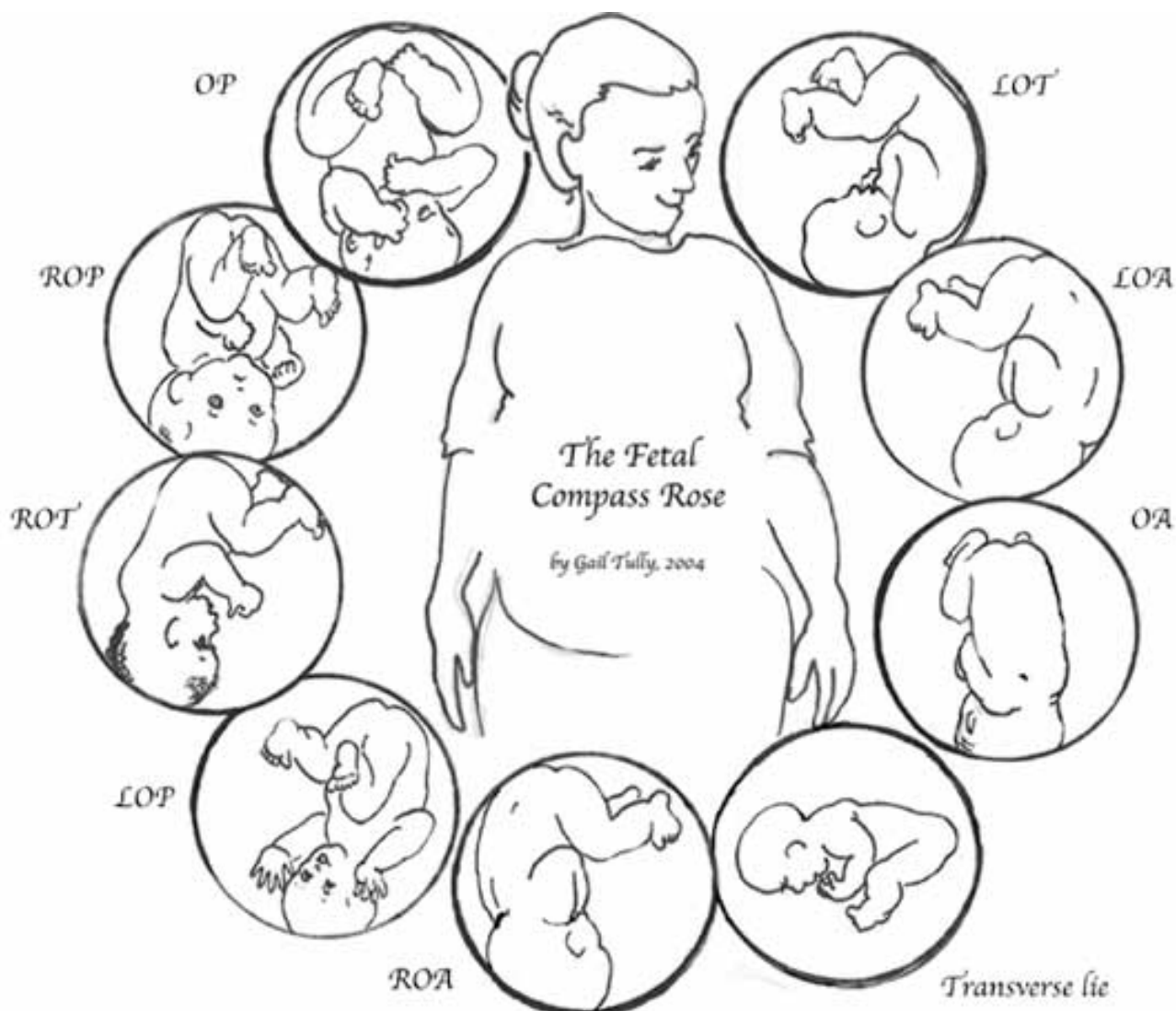
Fetal Positions Defined

PRINT

[Belly Mapping](#)

Fetal Positions

North, South, East and West. These are the positions on a compass. The equator divides North and South and the Greenwich Meridian divides East from West. (We here along the Mississippi River have a natural landmark that we think divides east and west, but that must be our local perspective.)



We use parts of the mother and baby's bodies as landmarks when we talk about fetal positioning. The baby's head has four places of interest in "mapping" out the position. The occiput bone is the most common landmark to come out of the mother first, among the various landmarks of the baby. The crown of the head is most likely to come out first and the crown is where three skull bones meet so the occiput is chosen to represent a head down baby coming with the crown first. If this head down baby has her head tipped her parietal bone will come out first. We still label her position with the occiput, though she is "asynclitic." More on that another day. The two remaining landmarks on the head are the brow and the

mentum or chin.

The mother's landmarks are her front (where her pubic bone is) and that is called Anterior; her back, called Posterior; and her sides, both called, Transverse. Transverse just means side and in the head down baby simply means the baby faces a hip.

Click "Read More," below to see more drawings and read labels or else read Belly Mapping below for the full story.

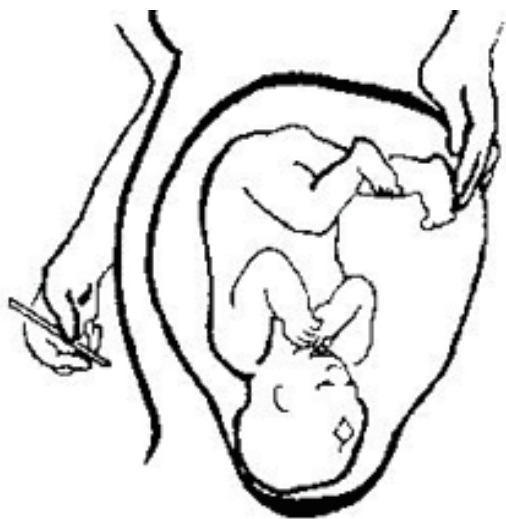**OA,
OP,
LOT, and
ROT**

OA, OP, LOT and LOP are the four basic fetal positions.

They stand for

**Occiput Anterior,
Occiput Posterior,
Left Occiput Transverse, and
Left Occiput Posterior.**

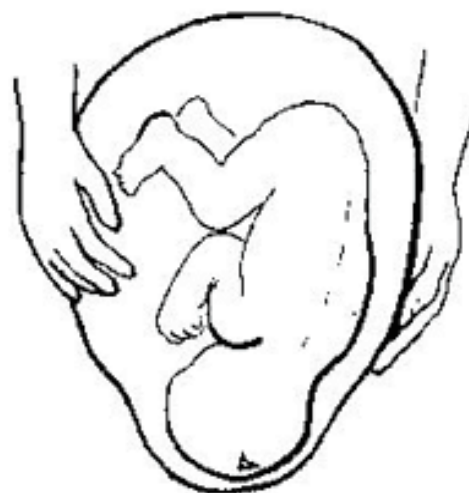Katy's baby, the baby in the banner at the top of the Spinning Babies Web Site (see it there?), is in the Left Occiput Transverse position, or "LOT."



**Right Occiput
Posterior (ROP)**



**Left Occiput
Posterior (LOP)**

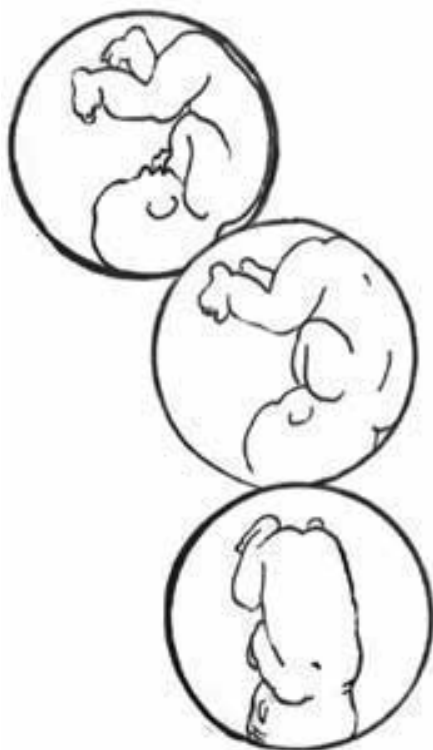


**Left Occiput
Anterior (LOA)**

We can add four more positions, like NE, NW, SE and SW only for babies. These would be,

**LOA,
LOP,
ROA and
ROP**

**These letters stand for
Left Occiput Anterior (LOA),
Left Occiput Posterior,
Right Occiput Anterior, and
Right Occiput Posterior.**



**Here are the three anteriors. Left Occiput Transverse, which rotates easily to an occiput anterior baby most of the time (with an epidural a few more will rotate posterior than will in a birth without an epidural, see Labor and Birth and look for the Lieberman Review).
The second baby in this threesome is Left Occiput Anterior and the third is Occiput Anterior.**
